

Case report

A RARE CASE OF FATAL SUICIDAL CUT THROAT INJURY- A CASE REPORT

Dr. C S Kulkarni, Dr. SS Agashe, Dr. SC Mohite

Dr. C S Kulkarni MBBS, MD, Assistant Professor, Dept. Of Forensic Medicine, TNMC & BYL Nair Ch. Hospital, Mumbai Central, Mumbai.

Dr. SS Agashe, MBBS, Junior Resident, Dept. Of Forensic Medicine, TNMC & BYL Nair Ch. Hospital, Mumbai Central, Mumbai

Dr. SC Mohite, MBBS, MD, LLB, DNB, Prof. & Head, Dept. Of Forensic Medicine, TNMC & BYL Nair Ch. Hospital, Mumbai Central, Mumbai.

Type of paper : Case Report
Number of pages : 06
Number of photographs : 03

Corresponding Author :
Dr. C S Kulkarni,
Assistant Professor,
Department of Forensic Medicine and Toxicology,
TNMC & BYL Nair Ch. Hospital,
Mumbai Central, Mumbai
9220743877, kulkarnidrchaitanya@gmail.com

Case report

A RARE CASE OF FATAL SUICIDAL CUT THROAT INJURY- A CASE REPORT

Dr. C S Kulkarni, Dr. SS Agashe, Dr. SC Mohite

Abstract

Cut throat injuries are mostly homicidal and rarely suicidal life threatening injuries. Mental illness, low socioeconomic status and unemployment are the major risk factors associated with self-inflicted injuries. We received a dead body of middle aged man for postmortem examination with cut throat wound over neck. After obtaining proper medical history (the deceased was a known schizophrenic), crime scene investigation and meticulous autopsy, we came to the conclusion that the cut throat injury in present case was suicidal in nature. This helped the investigation agency to rule out any possibility of homicidal manner of death. The detailed findings of the present case are discussed in this paper.

Keywords-Self Inflicted Injury, Homicide, Suicide, Mental Illness, Cut Throat Injury.

Case report

A RARE CASE OF FATAL SUICIDAL CUT THROAT INJURY- A CASE REPORT

Dr. C S Kulkarni, Dr. SS Agashe, Dr. SC Mohite

Abstract:

Cut throat injuries are mostly homicidal and rarely suicidal life threatening injuries. Mental illness, low socioeconomic status and unemployment are the major risk factors associated with self inflicted injuries. We received a dead body of middle aged man for postmortem examination with cut throat wound over neck. After obtaining proper medical history (the deceased was a known schizophrenic), crime scene investigation and meticulous autopsy, we came to the conclusion that the cut throat injury in present case was suicidal in nature. This helped the investigation agency to rule out any possibility of homicidal manner of death. The detailed findings of the present case are discussed in this paper.

Keywords: Self Inflicted Injury, Homicide, Suicide, Mental Illness, Cut Throat Injury.

Introduction:

Suicide is one of the ten leading causes of death in the world accounting for more than 400,000 deaths annually. The incidence and pattern of suicide vary from country to country where cultural, religious and social values play some role in this regard.¹ Psychiatric disorder is an usual if not invariable antecedent to suicide. Several studies have documented an excess mortality due to suicide among psychiatrically ill persons². Besides hanging and self-shooting, self-inflicted sharp force injuries are well-recognized method of suicide; the throat/neck region is a site which – thus easily accessible – might rarely be involved in such fatalities.³

Cut throat injuries may be homicidal or suicidal and they are potentially life threatening injuries because of the many vital structures in the neck which may be affected leading to severe hemorrhage, air embolism or respiratory obstruction and death.⁴ Therefore proper history, meticulous autopsy and crime scene investigation are important tasks for determination of manner of death, whether suicidal, accidental or homicidal for a Forensic pathologist in such cases. To our knowledge, this case presents a rare case of suicidal cut throat injury with psychiatric disorder.

Case report:

We received a dead body of middle aged 45 years old man for medicolegal postmortem at the mortuary of tertiary care institute. After going through the requisition papers, we came to know that the deceased was a known case of psychiatric illness (schizophrenia) and was under treatment for it. He used to sell roasted grams on the roadside but left the same since 2 years. Since 4 days he was talking irrelevantly. At midnight he came out of his room and cut his throat with a knife. The act was eye witnessed by two young boys. He was brought to casualty of the same institute where he was declared dead before admission.

Crime Scene examination:

The house was situated in a slum, having one room with open space in front. The deceased was lying in supine position in pool of blood over the floor in the open space. There was spurting of blood on the floor where the dead body was found. A knife was found lying next

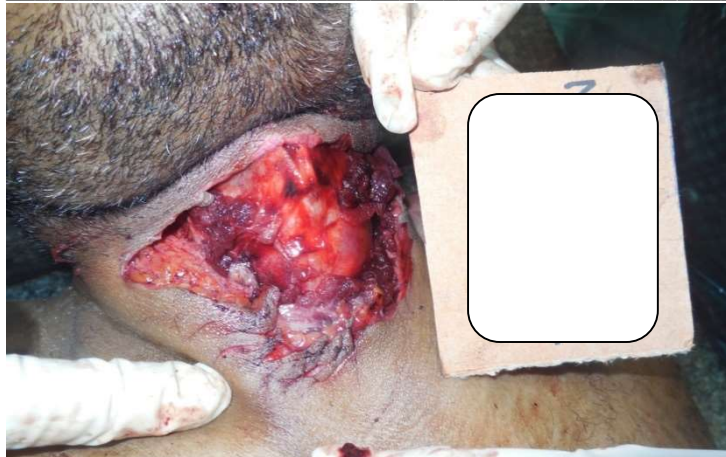

Image 1: Cut throat wound over neck with multiple hesitation cuts

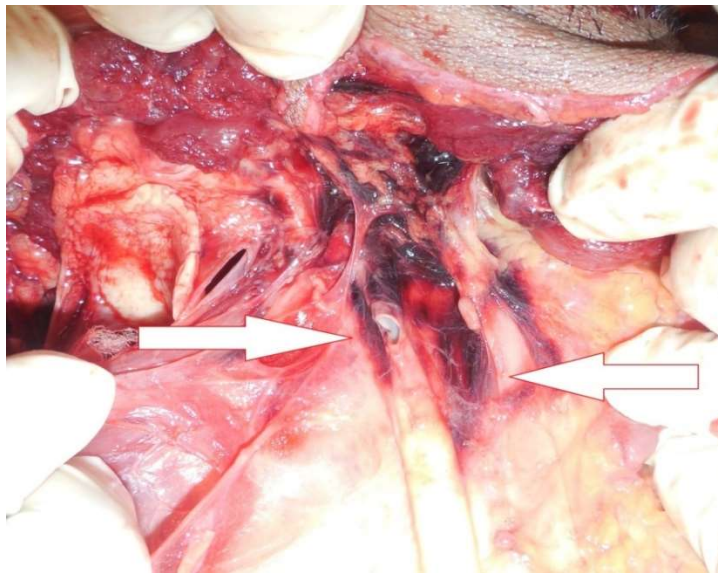


Image 2: Incised injury to left common carotid artery and left internal jugular vein.

to him. His clothes and the knife were seized by the police at the spot. The police sent the blood samples from the spot and blood stained knife for determination of blood group.

Autopsy findings:

External examination- The body was 165cm in length and weighed 51kg with dried blood stains over face, neck, both hands. Rigor mortis was fully developed all over the body and hypostasis was faintly appreciated over back. There were no signs of decomposition. Time since death was estimated as 9-12 hours before post-mortem examination consistent with the time of the alleged act.

External injuries: A single gaping cut throat incised wound of size 15cm in length and with maximum breadth of 3.2cm was present over the anterior aspect of neck. The depth of the wound over the left upper end was 4cm and superficial at lower end on right side i.e. subcutaneous tissue deep. It was directed obliquely downwards from left submandibular region to right muscular triangle of neck. It was 6 cm below lt. mastoid prominence & 10 cm below the right mastoid prominence.

In midline it was 8cm below chin and 5cm above the suprasternal notch. Near the lower border just lateral to midline on right side there were 4 superficial hesitation cuts with tailing of sizes 1x0.3cm, 0.8x0.3cm, 0.8x0.2cm and 0.7x0.2cm respectively. There were no other external injuries on the body including defense wounds. No evidence of contusion of the margins.

Internal examination: On careful dissection of the wound, it showed clean cut edges involving skin, superficial fascia, platysma, sternocleidomastoid muscle on left side, left internal jugular vein, left common carotid artery and anterolateral wall of laryngopharynx junction with hematoma over the soft tissues. On the right side there was no evidence of any injury to muscles and deeper tissues. These features were suggestive of sharp edged light weight weapon used for cutting of neck with multiple attempts. Stomach was empty and all the internal organs were intact and pale. Death was opined due to hemorrhage and shock as a result of cut throat injury (unnatural).



Image 3 Blood spurting at the crime scene.

Discussion:

Self inflicted sharp force injuries over neck are uncommon but well recognized method in suicidal fatalities. The distinction between homicidal, suicidal and accidental injuries is not an easy task for autopsy surgeon who needs to evaluate neck injuries in each case.³

As evident from the literature available from the past studies like Anand Ret al², Adoga AA⁴, Jain A et al⁵ mental illness, unemployment and low socioeconomic status are the strongest indicators of suicide. Also a 2005 report from National

association of state mental health program found mortality gap of 25 years between schizophrenia patients and general population concluded that 45% of mortality was related to suicide and other unnatural causes. Self mutilation is a common finding in schizophrenic's⁶. In the present case the deceased was known schizophrenic, belonged to low socioeconomic status and unemployed. He had visual hallucinations that some unknown person has killed his father. He was talking irrelevantly like "Mere Baap Ko Maar Daala" since 3-4 days before committing suicide.

Self inflicted injuries are generally located on accessible parts of body like neck, chest, flexor aspect of forearm etc. Suicidal cut throat injuries for a right handed person is seen over left side of neck directed from left to right and having greater depth at beginning with tailing on other side with hesitation cuts⁷. Hesitation cuts are described in 60-80% of such cases⁸. In present case, injury was present over the neck. The depth of the injury was more on left side and directed from left to right, above downwards with multiple superficial hesitation cuts at lower end suggestive of multiple attempts with divided state of mind. There were no defense wounds over the body of deceased. All these facts strongly point towards suicidal manner of cut throat injury.

Crime scene investigation must be considered to establish the manner of death in such cases of cut throat injuries. In our case after going through the crime scene report. It was revealed that there were no signs of struggle, deceased was found in pool of blood and weapon was seized by police authorities from crime scene. The incidence was witnessed by 2 young children. The weapon seized by the police was a light weight sharp edged iron blade with wooden handle. Blood was preserved for the determination of blood group of the deceased so as to match with the blood group of the blood preserved by the police from the crime scene and on the weapon. We had sent the blood to Forensic science laboratory and also to the FDA approved blood bank of the same institute. The blood group of the deceased was 'O' positive as reported by blood bank.

Forensic science laboratory reports have a major role to play in deciding the manner of death in such cases. Their reports are directly admissible in court of law as per the section 293 CrPc.⁹ Unfortunately all the blood group test results from the Forensic Science Laboratory were inconclusive including the blood sample preserved by the police from the crime scene. Hence it could not be matched with the blood group of the deceased.

Conclusion:

On prima facie evidence most of the cut throat injuries look homicidal but proper history, crime scene investigation and meticulous autopsy by forensic pathologist would correctly establish the suicidal manner of death in such suspicious cases. For the basic analytical tests like detection of blood group, the report from any FDA approved blood bank should be admissible in the court of law.

References:

1. Saeed A, Bashir MZ, Khan D, Iqbal J, Raja KS, Rehman A. Epidemiology of suicide in Faisalabad. *J Ayub Med Coll Abbottabad* ;2002;14(4):34–7.
2. Anand R , Trivedi J K , Gupta S C , Suicidal communication in psychiatric patients, *Indian Journal of Psychiatry*; 1983, 25(2), 121-128.
3. Solario B , Buschmann T C , Tsokos M, Suicidal cut throat and stab fatalities: three case reports. *Rom J Leg Med* [19] 161-166 [2011], DOI: 10.4323/rjlm.2011.161, © 2011 Romanian Society of Legal Medicine
4. Adoga AA, Suicidal cut throat injuries: Management modalities, Mental illnesses- Understanding, Prediction and control, Prof. Luciano Labate (Ed.), ISBN:978-953-307-662-1, In Tech, Available from :<http://www.intechopen.com/books/mental-illness-understanding-prediction-and-control/suicidal-cut-throat-injuries-management-modalities>.
5. Jain A , Yadav J , Kumar G , Dubey B P, Fatal Cut-Throat Injury Labeled as Suicide after Meticulous Autopsy: Case Report , *J Indian Acad Forensic Med*. April-June 2014, Vol. 36, No. 2, 206-208
6. Parks J, Svendsen D, Singer P and Foti M. Morbidity and Mortality in People with Serious Mental Illness National Association of State Mental Health Program Directors (NASMHPD) Medical Directors Council, Alexandria, VA 22314. Available at <http://www.nasmhpd.org/docs/publications/MDCdocs/Mortality%20and%20Morbidity%20Final%20Report%208.18.08.pdf>.
7. Vij K, Injuries by sharp force, *Textbook of forensic medicine and toxicology*, 6th edition 2014, Reed Elsevier India Pvt. limited, p.214-223.
8. Karlsson T, Ormstad K, Rajs J. Patterns in sharp force fatalities—A comprehensive forensic medical study: Part 2. Suicidal sharp force injury in the Stockholm area, 1972–1984. *J Forensic Sci*. 1988; 33: p.448–61.
9. Universal's criminal manual 2009 edition, Universal law publishing Co. Pvt. Ltd. ,Delhi, p.168.