

Case Report

DEATH DUE TO GAGGING BY AN ONION: A CASE REPORT

Dr. S. H. Bhosle, Dr. K. U. Zine, Dr. G. D. Niturkar, Dr. R. N. Wasnik

Authors:

Dr. Santosh H. Bhosle, MD, Associate Professor, Department of Forensic Medicine, Govt. Medical College, Aurangabad (Maharashtra).

Dr. K. U. Zine, MD, Professor & Head, Department of Forensic Medicine, Govt. Medical College, Aurangabad (Maharashtra).

Dr. G. D. Niturkar, MD, Associate Professor, Department of Forensic Medicine, Govt. Medical College, Aurangabad (Maharashtra).

Dr. R. N. Wasnik, MD, Associate Professor, Department of Forensic Medicine, Govt. Medical College, Aurangabad (Maharashtra).

Number of pages: 06

Number of Photographs: 03

Author for correspondence:

Dr S. H. Bhosle, M.D. Forensic Medicine

Associate Professor

Department of Forensic Medicine,

Government Medical College,

Aurangabad (MAHARASHTRA).

431001.

9673680101, santoshbhosle09@gmail.com

Case Report

DEATH DUE TO GAGGING BY AN ONION: A CASE REPORT

Dr. S. H. Bhosle, Dr. K. U. Zine, Dr. G. D. Niturkar, Dr. R. N. Wasnik

Abstract:

Deaths due to mechanical asphyxiation constitute one of the most important medico-legal cases dealt by autopsy surgeons. Of these, death by gagging is very infrequent. The term “gagging” is used to describe the blockage of the internal respiratory passage by ramming certain objects into mouth. Usually, gag is used to prevent the victim from shouting for help during crime. Mostly soft materials like cloth are used as gag and use of hard material is unforeseen occurrence. Here we present a case of death of six years old girl due gagging by an onion.

Key words: Gag, Hard material, Onion.

Case Report

DEATH DUE TO GAGGING BY AN ONION: A CASE REPORT

Dr. S. H. Bhosle, Dr. K. U. Zine, Dr. G. D. Niturkar, Dr. R. N. Wasnik

Abstract:

Deaths due to mechanical asphyxiation constitute one of the most important medico-legal cases dealt by autopsy surgeons. Of these, death by gagging is very infrequent. The term “gagging” is used to describe the blockage of the internal respiratory passage by ramming certain objects into mouth. Usually, gag is used to prevent the victim from shouting for help during crime. Mostly soft materials like cloth are used as gag and use of hard material is unforeseen occurrence. Here we present a case of death of six years old girl due gagging by an onion.

Key words: Gag, Hard material, Onion.

Introduction:

The term ‘asphyxia’ is commonly applied to a variety of conditions in which interference with respiratory exchange plays greater or lesser part¹. Deaths due to mechanical asphyxiation constitute one of the most important groups subjected to medico-legal autopsy. The causes of mechanical asphyxiation include hanging, ligature strangulation, throttling, smothering, gagging, choking, drowning and traumatic asphyxia etc. The violent asphyxial death caused by obstruction of internal airway by some object which includes gagging and choking is an infrequent occurrence. (1) In majority of these deaths, findings other than signs of asphyxia related to cause of death on external examination are lacking. Also, as decomposition sets in, the signs of asphyxia get obscured leaving findings of blockage of air passage as the only proof.

Choking refers to the blockage of internal airways, usually between the pharynx and the bifurcation of the trachea. The choking deaths are mostly accidental in manner. Gagging involves the securing of an obstruction across the mouth or within it². The manner of death in gagging is mostly homicidal. This form of asphyxia is mostly caused when pad or piece of cloth is thrust into the mouth. The article/gag not only fills up the mouth but also causes obstruction to air entry through the back of throat from nostrils.³

Here in this case report, we present the death of six years old girl due to complete obstruction of oro-pharynx and naso-pharynx by the onion. The death was a result of harsh punishment given by father by gagging her with an onion.

Case History:

On the day of incident in July 2016, after returning home from work the father of deceased girl was checking her academic progress at around 09.00 pm. At the same time, her mother was engaged in household activities. Father of child is a short tempered person and he got angry as she fails to recite numerical, as a punishment for her inability to narrate numerical repeatedly, he picked up an onion by side and used it as a gag to fill her mouth. As a result of this penalty, she started crying which augmented the anger of the father. Afterwards, in heat of anger he thrust that onion deeper in her mouth due to which she struggled for breath. On noticing this, her mother rushed to her and tried to remove onion by fingers and by thumping her back. But, she could not succeed and meanwhile, the girl collapsed. They immediately shifted her to a nearby private hospital where the girl was dead at the time of arrival. The history of accidental engulfing of onion by girl while playing was given by the parent to the attending physician.

Although, the attending physician did not register the case and informed the police; he orally declared the death and instructed relatives to take the body to Government hospital and inform the police. However, they carried the dead body to home and buried it with rituals.

The mother of the girl knowing the exact incident could not forgive the assailant father whose act resulted in death of her daughter. She consulted the child's maternal grandfather and lodged the police complaint after two days. Afterwards, exhumation was carried out and autopsy was conducted in mortuary of Government medical college, Aurangabad on third day after the incident.

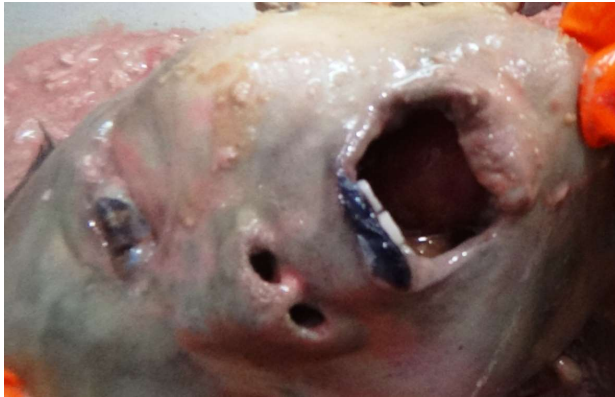

Fig.1: Intact whole Onion in Oral cavity

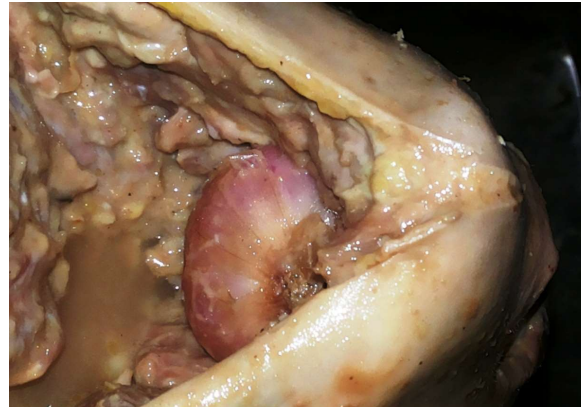


Fig.2: Intact onion obstructing the oro-pharynx and naso-pharynx

Autopsy Findings:

The external examination during autopsy showed signs of decomposition in the form of foul smelling swollen body with greenish discoloration all over and peeling of skin at places. No any visible external injury was evident on body except an abrasion of size 2 cm x 0.5 cm present over middle part of upper lip. Also, the internal examination of head and trunk did not detect any trauma to organs. On opening mouth, an intact whole onion was evident at posterior part of mouth (**fig.01**). On internal examination it was found impacted in the oro-pharynx and posterior part of onion touching the posterior pharyngeal blocking the airway from naso-pharynx (**fig.02**). The internal examination showed multiple contusions of varying sizes at posterior part of tongue, bilateral tonsillar pillars (Palatoglossal and Palatopharyngeal arches) and soft palate indicating extreme stretching by onion at the site (**fig. 03**). The onion weighed 25 grams having maximum circumference 11.8 cm. The cause of death was opined as, "Death due to Gagging by Onion".

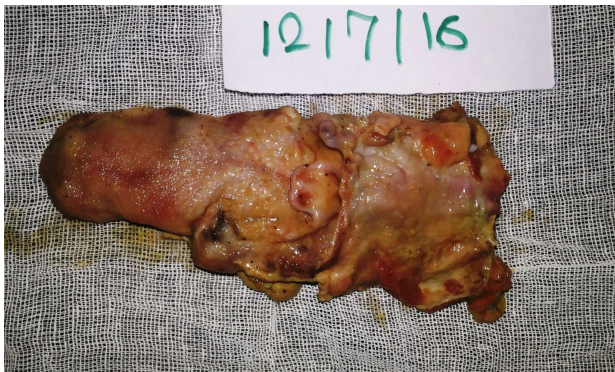

Fig.3: Contusions at Posterior part of tongue and adjacent structures

Discussion:

Nowadays, education of children is the most important concern for the parents. However, punishment is not the good way to teach them as it may lead to insecurity, lack of confidence and degradation of their academic progress. In India, it has been observed that, girls are subjected more frequently to punishments for their so called wrong doings. Also, girls get harsher punishments as compared to boys. In the present case, a six years' girl was gagged to death by the onion as a mean of punishment for her poor progress in the school.

When gag is thrust into the mouth death is more likely to be result of pharyngeal obstruction and not due to nervous stimulation¹. Gag usually means rolled up cloth or other soft material pushed into the mouth sufficiently deep to block the pharynx which will cause asphyxia⁴. Cotton cloth is the most common soft material used as gag. However, other soft materials such as toilet paper, tissue paper were also reported by researchers⁵⁻⁷. But, in the present case a hard material onion had been used as gag which was rammed in mouth and got obstructed in oro-pharynx.

Gagging is mostly homicidal in nature and rarely suicidal. Homicidal gagging is common in children, females and old age group where least resistance is offered by victims. Although homicidal gagging is rare in healthy adult, the cases had been reported⁵⁻⁷. Yadav et al.⁸ reported a case of homicidal gagging which was concealed by fire and the rolled up cloth used as gag. Suicide by gagging is usually observed among persons suffering from psychiatric disorder.

The complaint was launched on third day of the incident by the mother. Afterwards, the crime was registered under 201, 302 IPC by the police against the father of deceased. However, this crime could be identified earlier if the death was registered and informed to the police by the private hospital where death was orally declared. In India, oral declaration of brought dead cases without informing the police by the private hospitals is not uncommon practice, if death is due to natural disease and/ or foul play is not suspected. Gag is commonly used to prevent the victim from shouting for help and death is usually not intended⁴. Such deaths, though unintentional, are still homicides if the victims die during the commission of a crime⁹. As the present incident occurred in the heat of anger, the death being unintentional without premeditation could be the ground for defense. However, the assailant's knowledge regarding likely fatality of such act would be of decisive consideration in present case.

The gag used may be completely thrust deep inside mouth and may not be visible on external examination. Thus, meticulous examination of naso-pharynx and oro-pharynx during autopsy will provide valuable evidence as to the cause of death. The signs of asphyxia being lacking are not useful in decomposed bodies. In such deaths, it's the discovery of the gag obstructing the airways that makes the diagnosis. During autopsy, contusions on the pharyngeal regions, palate, and base of tongue should be meticulously looked as it is indicative of marked stretching by the object. Parents should be counseled regarding bad effects of punishments and encouragement to use better methods for academic enhancement of their children.

Reference:

1. Francis E Camps. Gradwohl's Legal Medicine. Third Ed. Bristol: John Wright & Sons LTD; 1976. p. 335-344.
2. Purdue BN. Asphyxial and Related deaths. In: Mason JK and Purdue BN. editors. The Pathology of Trauma^{3rd} Edition, London: Arnold Publishers; 2000. p. 230-252
3. Karmakar RN (Ed). Mukherjee's Forensic Medicine and Toxicology. 3rd ed. Kolkata: Academic Publishers; 2007;623.
4. Reddy K.S.N. The Essentials of Forensic Medicine and Toxicology. 33rd Ed. New Delhi: The Health Science Publishers; 2014. p. 361-362.
5. Saint Martin P, Lefrancq T, Sauvageau A. Homicidal smothering on toilet paper- a case report. Journal of Forensic & Legal Medicine, 2012; 19(4):234-35.
6. Kurihara K, Kuroda N, Murai T. et al. A case of homicidal choking mistaken for suicide. Med Sci Law, 1992; 32(1): 65-67.

7. Tyagi A, Kumar-Vashisht Y, Panchal K, Haneef-Beg M. Gag Deadens but doesn't Mute the Crime: a Case Series of Homicidal Gagging. *International Journal of Medical Toxicology and Forensic Medicine*. 2015; 5(4): 222-6.
8. Yadav A, Alam F, Kothari NS et al. A rare case of homicidal gagging concealed by fire. *Medico-legal Update*, 2013; 13 (2): 8-11.
9. Dimaio VJ. Homicidal asphyxia. *Am J Forensic Med Pathol*. 2000;21(1):1-4.