

Case Report

MIDDLE-EAR HAEMORRHAGE CONFIRMS THE CAUSE OF DEATH IN DECOMPOSED BODY FOUND IN THE SEA AFTER THE HELICOPTER CRASH TRAGEDY: CASE REPORT

Dr.D.V.Bhore, Dr.M.B.Bhadange, Dr.S.D.Nanandkar

Authors

Dr.D.V.Bhore, MD, Assistant professor, Department of Forensic Medicine and Toxicology, Grant Government Medical College and Sir J J Hospital, Mumbai 400008.

Dr.M.B.Bhadange, Resident Doctor, Department of Forensic Medicine and Toxicology, Grant Government Medical College and Sir J J Hospital, Mumbai 400008.

Dr.S.D.Nanandkar, MD, Professor and Head, Department of Forensic Medicine and Toxicology, Grant Government Medical College and Sir J J Hospital, Mumbai 400008.

Type of paper : Case Report
Number of pages : 05
Number of photographs : 02

Corresponding Author :

Dr.Dattatray Vitthal Bhore

Assistant Professor,

Department of Forensic Medicine and Toxicology

Grant Government Medical College and

Sir JJ Hospital, Mumbai 400008.

dattabhore130@gmail.com

Case Report

MIDDLE-EAR HAEMORRHAGE CONFIRMS THE CAUSE OF DEATH IN DECOMPOSED BODY FOUND IN THE SEA AFTER THE HELICOPTER CRASH TRAGEDY: CASE REPORT

Dr.D.V.Bhore, Dr.M.B.Bhadange, Dr.S.D.Nanandkar

Abstract:

Drowning is a form of asphyxia due to aspiration of fluid into air passages, caused by submersion in water or other fluid. Drowning is one of the most difficult modes of death to prove at post-mortem, especially when the body is not examined in a fresh condition. The diagnosis is basically one of exclusion based largely on the history and investigative reports of the case. If such dead bodies recovered from sea gets decomposed and brought for autopsy then it makes the task difficult for autopsy surgeon to ascertain the cause of death. This paper describes that on meticulous examination, the autopsy doctor could be able to reach to a conclusion by ruling out other possible causes of death and find out less encountered findings like middle ear haemorrhages along with positive diatoms test.

Key words: salt water drowning, decomposed body, middle ear haemorrhage, diatoms.

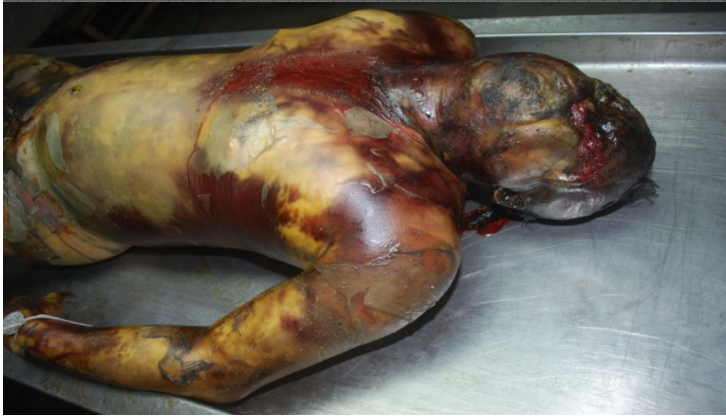Introduction:

Drowning is a mode of violent asphyxia death. About 150,000 people die from drowning each year around the world. [1] Drowning is mostly accidental in nature and commonly succumbed peoples are no swimmers i.e. in children or incapacitated persons by any means. Second most nature of drowning is suicidal one. Homicidal drowning is very rare and seen in infants and children. In typical wet drowning all possible signs of drowning will be found at autopsy but in atypical drowning reliable signs of drowning will not be seen. In advanced putrefaction the diagnosis is difficult because signs are completely absent. In our set up most common cases of violent asphyxial death are hanging followed by drowning.

Case Report:

A dead body of 58 years old male brought to morgue of forensic medicine department of sir JJ hospital for post-mortem examination. As per accidental death report and police inquest reports, the deceased was missing since eight days after helicopter crash in Arabian Sea. Deceased was pilot by occupation and had an experience of around 50000km of helicopter driving. On the day of incidence, the deceased and his co-pilot took off from ONGC platform for night training in the Arabian Sea, but after half an hour from their take off they were untraced and uncontacted. So navy authority thought they might have met with an accident of helicopter crash in the Arabian Sea. For that they started search operation in the Sea. However, they were unable to find them. It was only when one of the pilots was found dead and found near sea shore after eight days of incidence that they come to conclusion.

On **External** examination: A body was in advanced decomposition state with foul smell emanating from the body. Evidence of gas stiffening noted over whole body. Adipocere formation seen over chest, shoulder, back, abdomen, shoulder, upper and lower limbs. Bloating over face, abdomen and external genitalia. Eyes were swollen and protruded out of the eye sockets. Mouth was closed but on opening of it shown tongue clinched between anterior teeth. Separated and loosened black white colour hairs of moustaches and beard noted over face. Nose Bridge and nostrils flattened and deformed due to decomposition. Scalp hair black colour loosened and easily pluckable. No external injuries noted over face, neck and scalp. No froth noted at orifices of nose and mouth. Abdomen showed distension



1. Photograph shows decomposed body.

due to post-mortem gas formation. Marbling of veins noted over chest, upper and lower limbs. External genitalia showed swelling and bloating features. Peeling of epidermis seen at hands and feet. On palpation no any closed fractures were noted.

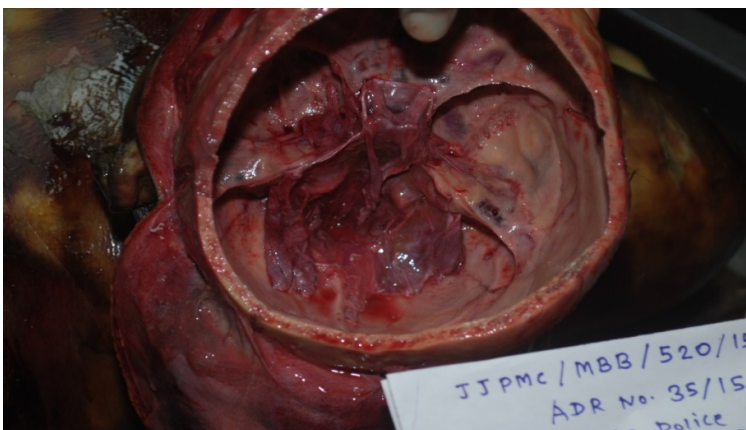
On Internal examination:

On internal examination all organs were found to be soft, flabby and partly autolysed. On opening of trachea no froth was noted but tracheal mucosa shows signs of decomposition. Both lungs autolysed and showed decomposition. Stomach content around 200cc partly digested food material, no specific smell perceived and mucosa was unremarkable. On opening of skull no under scalp injury was noted or no skull fracture. Brain matter was liquefied and meninges were intact. On stripping off the Dura at the base of skull, there was evidence of bilateral middle ear haemorrhage on right side. On dissection, haemorrhages noted with intact tympanic membrane. Visceral organs were preserved for chemical analysis, tissue bits for histopathological examination, tissue such as liver, lungs and bone marrow and water sample from the site where dead body found for diatom test and DNA samples were kept to rule out other possible causes of death.

Discussion:

It is said that drowning is a diagnosis of exclusion. If there are fresh reliable signs on post-mortem examination, then only one can ascertain the cause of death. So otherwise we have to exclude the typical features of drowning by noting them negative. Problem is even more when body is recovered from source after many days of drowning in advanced decomposition state. In that situation autopsy surgeon has big task to confirm the cause and mode of death, and whether it is ante mortem or post-mortem drowning. In many occasions such suspected drowned body can't be found out because of high tide and high water current of Sea. They get moved to distant places from actual site of incidence or such drowned body takes some hours to days to come on to the water surface after being sunk. In present case we did not get

2. Photograph shows middle ear haemorrhage



typical signs and features of drowning since body was in decomposed state. We did rule out head injury, probable myocardial infarction, alcohol consumption and co poisoning during autopsy and after receipt of chemical analysis and histopathological reports. Viscera were kept for alcohol, drugs, carbon monoxide poison but came negative. We arrived at our

conclusion that on opening of skull at its base we did find the middle ear haemorrhages which is one of the sign of drowning. Possible mechanism for production of it in drowning is due to barotrauma, i.e. the pressure differences between the middle ear and the surrounding water produce a relative vacuum and this negative pressure within the closed cavity leads to inward stretching of the tympanic membrane and haemorrhages. [2, 3, 4] Further we did also get the positive report for diatoms from our laboratory. We did meticulously ruled out the possible causes of middle ear haemorrhage such as head injury, CO poisoning, hanging, and myocardial infarction. On account of these two positive findings we gave the opinion as to cause of death was ante mortem drowning.

Conclusion:

To ascertain the diagnosis of violent asphyxial death due drowning is very difficult task for autopsy surgeon at post-mortem examination. If body found lately after being drowned especially when the putrefaction sets in and fresh signs of drowning are absent. So the only naturally preserved sign can be seen during autopsy is middle ear haemorrhage. Though middle ear haemorrhage is not pathognomonic sign of drowning but it can be seen in more than 50% of drowning cases. When we have to make diagnosis unequivocal then it is to be made with consideration of signs found at autopsy, ancillary test like diatoms and circumstantial evidences. In view of external findings, positive diatom test, evidence of middle ear haemorrhage and absence of any other pathology most probable opinion as to cause of death is asphyxia due to drowning.

Recommendation:

The present case being the case of fatal aircraft accident and as per the office of the director general of civil aviation (air safety directorate) circular no.6 of 2010 has laid down the certain notifications and autopsy guidelines for medical officers in cases of fatal aircraft accidents investigations. Some of them includes, to establish the causative agent for the crash and injuries sustained, to ascertain the presence of pre-existing disease or factor which might have incapacitated the individual and contributed to accident causation, examination of clothing and personal equipment, x-rays of whole part of body, all wounds, contusions and external injuries should be carefully noted, photographs should be taken of both the dorsal and ventral side of body, internal examination of the body cavity and organs, fractures in the rib cage anterior and posterior aspects should be looked for as it gives an indication of hyper flexion of the body, ruptures of heart, liver and diaphragm should be looked for, laceration of aorta indicates fractured ribs or decelerate forces, respiratory tract should be looked for soot or carbon particle, larynx oedema due to inhalation of toxic gases or foreign body, fractures or dislocations of vertebrae.

Specimen for histological examination includes pieces of all organs in 10% of formalin solution as early as possible should be preserved. 5ml of each blood and urine for ethanol with sodium fluoride as preservative, blood and muscle tissue for carbon mono-oxide are to be collected, preserved, stored and dispatched in frozen state without any chemical preservative, viscera for toxicological studies, brain tissue for lactic acid and muscle tissue for carbon mono-oxide are to be collected in polyethylene bag. [5]

References:

1. Reddy KSN. The Essentials of Forensic medicine and Toxicology. 33rd edition, Jaypee Brothers; 2014, p.365-374.
2. Vij K. Textbook of Forensic Medicine and Toxicology. 5th edition. India: Elsevier; 2011. P. 134-143.

-
3. Nelson R. Niles. "Haemorrhage in the middle ear and mastoid in drowning". The American Journal of clinical pathology; Volume 40, No-3, 1963, p.281-283.
 4. Chidanand C, Satish K.V. "Study of incidence of middle ear haemorrhage in drowning". Journal of Evidence Based Medicine Healthcare; Vol 2, issue 6, 2015, p.621-628.
 5. Government of India office of the Director General of Civil Aviation (Air Safety Directorate) Air Safety Circular No. 6 of 2010.